

Circulation

JOURNAL OF THE AMERICAN HEART ASSOCIATION



Magnetocardiographic Rhythm Patterns at Initiation and Termination of Fetal Supraventricular Tachycardia

R.T. Wakai, J.F. Strasburger, Z. Li, B.J. Deal and N.L. Gotteiner

Circulation 2003;107:307-312; originally published online Dec 9, 2002;

DOI: 10.1161/01.CIR.0000043801.92580.79

Circulation is published by the American Heart Association, 7272 Greenville Avenue, Dallas, TX 72514

Copyright © 2005 American Heart Association. All rights reserved. Print ISSN: 0009-7322. Online ISSN: 1524-4539

The online version of this article, along with updated information and services, is located on the World Wide Web at:

<http://circ.ahajournals.org/cgi/content/full/107/2/307>

Subscriptions: Information about subscribing to *Circulation* is online at
<http://circ.ahajournals.org/subscriptions/>

Permissions: Permissions & Rights Desk, Lippincott Williams & Wilkins, 351 West Camden Street, Baltimore, MD 21202-2436. Phone 410-5280-4050. Fax: 410-528-8550. Email:
journalpermissions@lww.com

Reprints: Information about reprints can be found online at
<http://www.lww.com/static/html/reprints.html>

Magnetocardiographic Rhythm Patterns at Initiation and Termination of Fetal Supraventricular Tachycardia

R.T. Wakai, PhD; J.F. Strasburger, MD; Z. Li, MS; B.J. Deal, MD; N.L. Gotteiner, MD

Background—Using fetal magnetocardiography (fMCG), we characterize for the first time the electrophysiological patterns of initiation and termination of reentrant fetal supraventricular tachycardia (SVT), the most common form of life-threatening fetal arrhythmia.

Methods and Results—In contrast to the expectation that reentrant SVT is initiated by spontaneous premature atrial contractions (PACs) and is terminated by spontaneous block, 5 distinct patterns of initiation and 4 patterns of termination were documented, with the most common patterns of initiation involving reentrant PACs. Waveform morphology and timing, including QRS and ventriculoatrial interval, were assessed. This enabled detection of such phenomena as Wolff-Parkinson-White syndrome, QRS aberrancy, and multiple reentrant pathways that were crucial for defining the rhythm patterns. In addition, fMCG actocardiography revealed an unexpectedly strong association between fetal trunk movement and the initiation and termination of SVT, suggesting that autonomic influences play a key role.

Conclusions—This study demonstrates that the patterns of initiation and termination of fetal SVT are more diverse than is generally believed and that the most common patterns of initiation involve reentrant PACs. The ability to discern such patterns can help elucidate the underlying mechanisms and guide antiarrhythmic drug therapy. fMCG provides a noninvasive means of analyzing complex tachyarrhythmia in utero, with efficacy approaching that of postnatal electrocardiographic rhythm monitoring. (*Circulation*. 2003;107:307-312.)

Key Words: electrophysiology ■ arrhythmia ■ tachycardia

Among the various forms of life-threatening fetal arrhythmia, supraventricular tachycardia (SVT) is the most common. With recent improvements in antiarrhythmic drug therapy, it is now possible to effectively treat SVT and other fetal arrhythmias in utero; however, this is a new and highly specialized area of cardiology and maternal-fetal medicine. The incidence of premature delivery and neonatal morbidity and mortality associated with SVT remains high, especially when patients are managed outside a tertiary care facility.¹

A shortcoming of present evaluation methods has been the limited ability to perform direct electrophysiological analysis of fetal rhythm in utero. Analysis of fetal rhythm via fetal ECG (fECG) is precluded by the poor quality of surface recordings; however, recently several groups have demonstrated the efficacy of fetal magnetocardiography (fMCG) for this application.²⁻⁵ The fMCG is the magnetic counterpart to the fECG, but it exhibits significantly better signal quality because it is largely unaffected by the high electrical resistance of the fetal skin, which attenuates the fECG and other fetal bioelectric signals.

Fetal SVTs are predominantly reentrant tachycardias, of which the most common type is atrioventricular reentrant tachycardia. Atrioventricular nodal reentrant tachycardia is

thought to be rare in the neonate.^{1,6} Reentrant SVTs are characterized by sudden initiation and termination. It is generally believed that SVT is initiated by a critically timed spontaneous premature atrial contraction (PAC) and is terminated by spontaneous block. The PAC causes delayed antegrade conduction through the AV node with subsequent retrograde conduction through the accessory connection, thus initiating orthodromic reciprocating tachycardia. In this study, we apply fMCG to characterize the electrophysiological, or more precisely magnetophysiological, patterns of initiation and termination of reentrant SVT. We identify 5 distinct patterns of initiation and 4 patterns of termination and implicate fetal movement as an important concomitant.

Methods

Our institutional review committees approved the study, and all subjects gave informed consent.

Study Cohort

The study cohort was comprised of 13 consecutive fetuses diagnosed with SVT (fetal heart rate >200 bpm) at our institutions between May 2001 and June 2002. SVT was defined by 1:1 atrioventricular concordance or contraction sequence, abrupt onset and termination, and minimal heart rate variability. Minimal heart rate variability was

Received August 1, 2002; revision received September 27, 2002; accepted September 30, 2002.

From the Department of Medical Physics (R.T.W., Z.L.), University of Wisconsin-Madison; Department of Pediatrics, Division of Cardiology (J.F.S.), Children's Hospital of Wisconsin, Milwaukee; and Department of Pediatrics, Division of Cardiology (B.D., N.G.), Children's Memorial Hospital, Chicago, Ill.

Correspondence to Ronald Wakai, PhD, Department of Medical Physics, 1300 University Ave, Madison, WI 53706. E-mail rtwakai@wisc.edu

© 2003 American Heart Association, Inc.

Circulation is available at <http://www.circulationaha.org>

DOI: 10.1161/01.CIR.0000043801.92580.79

TABLE 1. Characteristics of Intermittent Fetal SVT

	Subject							
	1	2	3	4	5	6	7	8
Gestational age, wk	28–0/7	22–5/7	31–6/7	30–1/7	27–2/7	17–3/7	22–4/7	27–0/7
Recording time, s	3000	3600	12 950	3600	7200	7200	6000	4800
Time in SVT, %	86.1	17.3	13.0	4.1	73.8	0.17	0.5	99.1
No. of SVT episodes	4	32	2	5	33	4	17	7
Duration of SVT episodes, s	646±643	19.5±26.4	839±923	29.9±24.5	161±145	2.4±1.7	1.8±1.0	679±675
Heart rate in SVT, bpm	185	290	230	205	215	230	305	190
Heart rate in normal sinus rhythm, bpm	125	150	140	130	115	155	155	100
WPW	no	yes	yes	no	no	no	no	no
Drug treatment before fMCG	Amio	No	Amio	no	IM digoxin	no	no	Amio+digoxin

Amio indicates amiodarone. Fractions are fractions of a week.

defined as confinement of heart rate within a band of 10 bpm for 90% of the time. One fetus that had not received antiarrhythmic medication was in SVT during entire the fMCG recording session, and 4 fetuses that had received a course of antiarrhythmic therapy were in sinus rhythm throughout. Data are presented from the remaining 8 fetuses. Antiarrhythmic drug therapy was begun before fMCG recording for subjects 1, 3, 5, and 8 and subsequent to fMCG recording for subject 2. Subjects 4 and 8 involved twin pregnancies. Subjects 2 and 8 participated in 2 recording sessions; however, for subject 8, data from only the second session are presented, because SVT was incessant during the first session.

fMCG Recording and Analysis

The fMCG studies were performed in the Biomagnetism Laboratory at the University of Wisconsin-Madison in accordance with institutional guidelines. The recordings were made in a magnetically shielded room with a 37-channel biomagnetometer (Magnes, 4D Neuroimaging, Inc). A brief ultrasound examination was performed to guide probe placement.

Typically, 5 to 13 recordings, each of 10-minute duration, were taken from each subject at several different probe positions. The recordings were digitized at 520 Hz and were bandpass filtered from 1 to 80 Hz. Maternal interference was removed using either a matched filter or a spatial filter.⁷

fMCG actocardiography⁸ was used to monitor fetal heart rate and fetal activity. This method of actography is based on the high sensitivity of the fMCG signal to the position and orientation of the fetal heart and is therefore specific for fetal trunk movements, which produce prominent episodic variations in signal amplitude that are distinct from abrupt variations attributable to such causes as rhythm changes and aberrant conduction. Actograms were obtained by plotting QRS amplitude as a function of time. QRS amplitude increases when the fetus moves toward the sensor, decreases when it moves farther away, and varies in a more complex manner when fetal orientation changes.

Postnatal Recording

Postnatal 12-lead ECGs were obtained within 24 hours of delivery. Postnatal transesophageal pacing was performed in 2 subjects.

Results

Table 1 summarizes the characteristics of SVT for each subject. Table 2 summarizes the observed initiation and termination patterns. Notable aspects of the tracings are described below. The results are presented by subject rather than by electrophysiological variable to depict intrasubject associations among these variables that typify specific forms of fetal SVT.

In subject 1, SVT initiated with spontaneous PACs, as exemplified in Figure 1. QRS aberrancy was always prominent at initiation and may have been potentiated by antiarrhythmic drug effect. The termination tracing shows a P wave after the last beat of SVT, implying that termination was attributable to spontaneous antegrade block in the AV node. This was the most commonly observed termination pattern in this study.

In subject 2, WPW was present continuously during sinus rhythm, evidenced by short PR interval (83 to 90 ms), prolonged QRS interval (69 to 82 ms), and delta wave presence. The beat that initiated SVT showed abrupt normalization of PR interval and QRS, with no change in PP interval or P-wave morphology (Figure 2). This implied that initiation was attributable to sudden antegrade block of the accessory connection in WPW, which allowed retrograde conduction through the accessory connection and subsequent SVT. VA lengthened during tachycardia when the QRS was aberrantly conducted. This finding supports the presence of an accessory AV connection ipsilateral to the location of the bundle-branch block.

In subject 3, who was studied in two sessions on consecutive days, SVT initiated with sinus acceleration (Figure 3). In contrast to initiation by PACs (Figure 1), the change in RR interval was gradual, with the two beats before SVT showing progressive RR shortening. QRS aberrancy was absent at and after initiation. Termination was again attributable to antegrade block. Notice, however, that the first 2 beats of sinus rhythm were preexcited. This marked the beginning of a 40-second period when WPW predominated. At all other times on day 1, WPW was absent. On day 2, initially the fetus was in SVT. After 15 minutes, SVT terminated and sinus rhythm was observed thereafter. Unexpectedly, WPW was present at all times during sinus rhythm on day 2 (Figure 3).

Subjects 4 through 8 showed frequent ectopy, compatible with reentrant PACs. The PACs usually had polarity opposite that of the sinus P waves and fixed VA interval similar to that seen during SVT. The PACs resulted in atrial bigeminal and polygeminal rhythms, in which instantaneous fetal heart rate cycled over a wide range in a precise manner. These rhythms alternated with normal sinus rhythm and SVT, resulting in

TABLE 2. Initiation and Termination Patterns

	Subject							
	1	2	3	4	5	6	7	8
Initiation								
Initiations observed	3	31	1	5	30	4	17	5
Spontaneous PAC	X							
Block of AC in WPW		X						
Sinus acceleration			X					
Reentrant PAC					X	X	X	X
Reentrant PAC with transition from fast to slow AC				X				
QRS aberrancy	X	X		X				X
Termination								
Terminations observed	3	31	2	5	30	4	17	5
Block in AV node	X	X	X			X	X	X
Block in AC	x						x	
Block after transition from slow to fast AC				X				
Block after dual AV pathway oscillation					X			
Transient bradycardia	X	X	X		x		X	

PAC indicates premature atrial contraction; AC, accessory connection; X, dominant pattern; and x, infrequent pattern.

complex heart rate and rhythm tracings. SVT initiated with a reentrant PAC and terminated with spontaneous block; however, subjects 4 and 5, respectively, showed variant patterns, indicative of involvement of multiple retrograde and dual antegrade pathways.

In subject 4, atrial polygemy with blocked PACs was present $\approx 90\%$ of the time. VA of the PACs was 167 to 173 ms, but during tachycardia, VA was 210 ms, implying the existence of 2 distinct reentry pathways. Normal sinus rhythm

was present less than 4% of the time. Despite this, 4 of the 5 episodes of SVT initiated from sinus rhythm, because the rhythm converted from polygeminal to sinus rhythm just before SVT. In all cases, SVT initiated with a reentrant PAC (Figure 4). Thus, reentrant PACs in sinus rhythm were highly effective in initiating SVT, whereas reentrant PACs in atrial polygemy were ineffective. The initiating PAC and the next atrial beat had short VA, but all succeeding atrial beats had longer VA, until SVT terminated by antegrade block of an

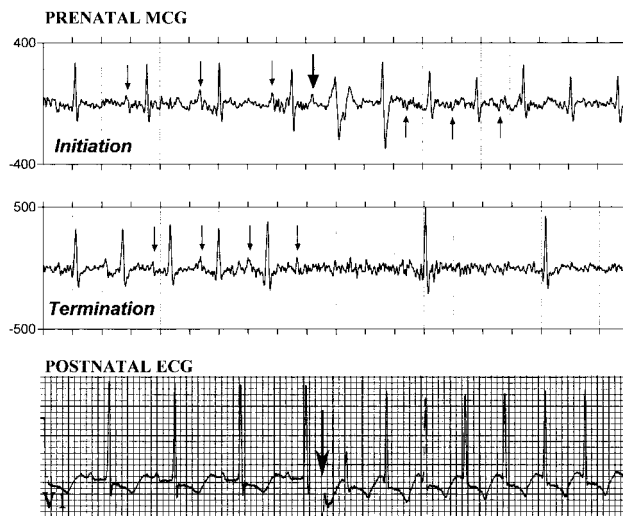


Figure 1. The top two panels are 4-second fMCG tracings showing initiation and termination of SVT in subject 1. SVT initiates with a spontaneous PAC (thick arrow). Thin arrows indicate P waves. The first few beats of SVT are aberrantly conducted. Termination is attributable to antegrade block in the AV node and is followed by marked transient bradycardia. The bottom panel shows postnatal initiation of SVT in lead V₁ by a single extrastimulus, indicated by the arrow, during transesophageal pacing procedure.

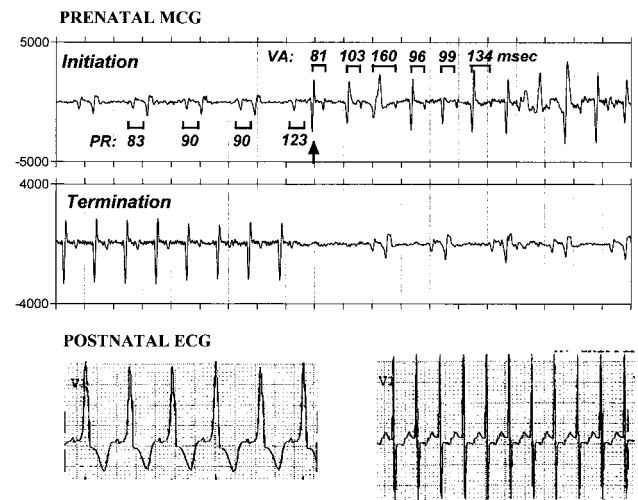


Figure 2. The top two panels are 4-second fMCG tracings showing initiation and termination of SVT in subject 2, a patient with Wolff-Parkinson-White syndrome. SVT initiates by block of the accessory connection, resulting in abrupt normalization of PR interval and QRS (arrow). PP interval is essentially unchanged at initiation. VA interval lengthens during tachycardia when the QRS is aberrantly conducted. Termination is attributable to antegrade block in the AV node. The bottom traces show the postnatal ECG from lead V₁ during sinus rhythm with WPW and during SVT.

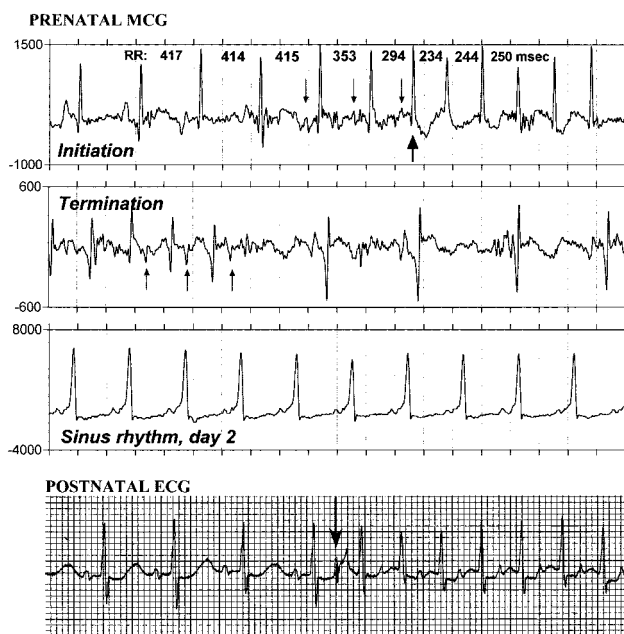


Figure 3. The top two panels are 4-second fMCG tracings showing initiation and termination of SVT in subject 3. SVT is initiated in association with sinus acceleration, as indicated by the progressive decrease in PP and RR interval before the first beat of SVT (thick arrow). Termination is attributable to antegrade block in the AV node. Notice that the transition to sinus rhythm shows preexcitation compared with QRS morphology before onset of SVT. The smaller arrows indicate P waves. The day-2 tracing shows WPW during sinus rhythm, evidenced by short PR interval, prolonged QRS interval, small P/QRS amplitude ratio, and ramped baseline. The bottom panel shows postnatal initiation of SVT in lead V₁ by a single extrastimulus, indicated by the arrow, during transesophageal pacing procedure.

atrial beat with short VA (Figure 4). This implies that the faster reentry pathway was used to initiate and to terminate SVT and that the slower one was used to sustain SVT. The termination pattern, as well as the initiation pattern, was therefore different compared with other subjects. Even though termination resulted from spontaneous block, the

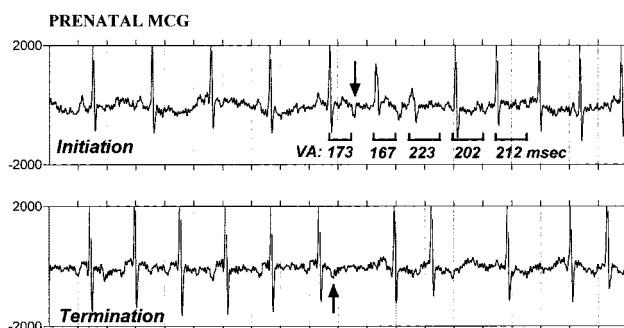


Figure 4. fMCG tracings (4-second duration) of initiation and termination of SVT in subject 4, twin B of a twin pregnancy. SVT initiates with a reentrant PAC (arrow). The first 2 reentrant atrial beats at the start of SVT have shorter VA than the succeeding beats. At termination, ventricular rate decelerates. Termination is attributable to antegrade block in the AV node of an atrial beat with short VA (arrow), consistent with the presence of two retrograde pathways, one of which initiates and terminates SVT and the other of which sustains SVT.

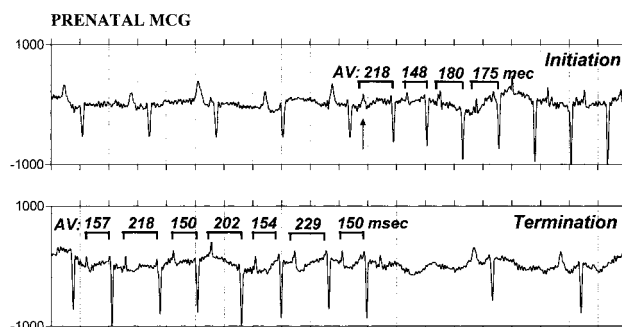


Figure 5. The top two panels are 4-second fMCG tracings showing initiation and termination of SVT in subject 5. Initiation is attributable to a reentrant premature beat (arrow). This beat shows longer AV, and the following beat shows shorter AV, compared with succeeding beats. Termination is attributable to spontaneous block in the AV node. Just before termination, AV oscillates markedly, whereas VA is nearly constant.

critical event was a transition from the slow to the fast reentry pathway.

Subject 5 showed a unique termination pattern. Termination was attributable to spontaneous block in the AV node, but the last RR interval of SVT was always short, and often several cycles of a long-short sequence were seen at termination (Figure 5). These variations in RR were attributable almost entirely to variations in AV, with VA remaining constant, and were preceded by gradual deceleration of ventricular rate. This pattern—ventricular deceleration, followed by AV oscillations—was sometimes seen during SVT without causing termination (Figure 6, bottom tracing at 175 seconds). These data strongly suggest the existence of dual antegrade AV nodal pathways as well as a single retrograde connection.

fMCG actocardiography revealed a remarkably strong association between fetal trunk movements and the initiation and termination of SVT (Figure 6). Although fetal movement was present only 10% to 25% of the time, the percentage of rhythm transitions occurring during episodes of fetal movement was $\approx 80\%$. Even when transitions did not coincide with fetal movement, they occurred during periods when the fetus was generally active. In subjects 2, 4, 6, and 7, the mean duration of SVT episodes was relatively brief and the fetus was active throughout SVT. In subjects 1, 3, 5, and 8, the episodes of SVT were much longer. The fetus was sometimes quiescent during SVT but became active around the time of SVT initiation and termination. In subjects 4 through 7, the heart rate tracings were dominated by large, regular oscillations attributable to reentrant PACs. In subject 4, the presence of sinus rhythm, as well as the initiation and termination of SVT, was associated with fetal movement, even when sinus rhythm was not followed by initiation of SVT.

The fMCG recordings showed good agreement with the postnatal ECG, shown in the lower panels of Figure 1 through 3. Fetuses 4 through 8 remain in utero. Concordance of SVT mechanisms was verified. All postnatal subjects showed fMCGs and postnatal ECGs consistent with atrioventricular reentrant tachycardia. WPW was confirmed postnatally in subject 2; however, it was not seen in subject 3, who showed only intermittent WPW in utero.

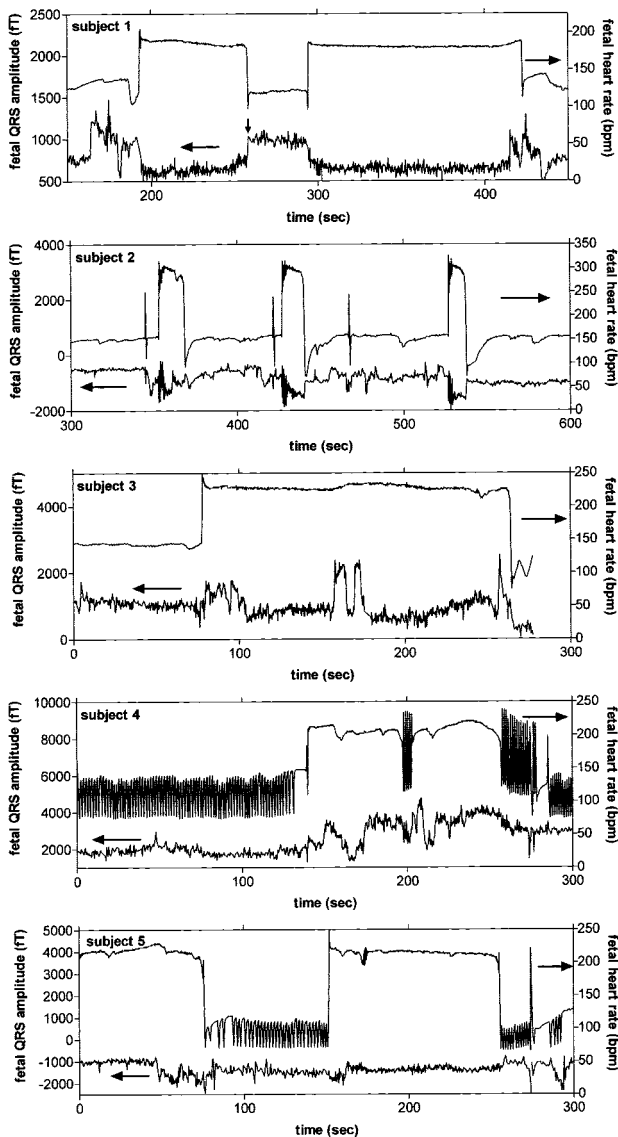


Figure 6. Actocardiograms from subjects 1 through 5 (top to bottom) depicting the association between fetal trunk movement and initiation and termination of SVT. In each graph, the upper tracing is the fetal heart rate and corresponds to the right axis. The lower tracing is the actogram, which is obtained from measurement of the QRS amplitude in a channel with high signal to noise ratio and corresponds to the left axis. The actograms are flat during periods of quiescence. Fetal movements produce prominent, episodic amplitude variations that persist for at least several seconds. Transitions between rhythms may result in amplitude changes that are abrupt and therefore distinct from those attributable to fetal movement, as exemplified by the transition marked with an arrow in subject 1. QRS aberrancy also results in beat-to-beat QRS amplitude (and heart rate) variations that are distinct from those attributable to fetal movement, as seen immediately after initiation of SVT in subject 2. Notice that in subjects 1 through 3, termination of SVT is followed by transient bradycardia. Subjects 4 and 5 show periods of large, highly regular heart rate oscillations attributable to reentrant PACs. Atrial polygemy with blocked PACs results in cycling of heart rate from normal to low. In subject 4, there are also periods of polygemy with conducted PACs, causing heart rate to cycle from normal to high. Notice that the rhythm changes from atrial quadrigemy to normal sinus rhythm at 133 seconds, shortly before the first episode of SVT.

Discussion

The two main findings of this study are that the electrophysiological patterns of initiation and termination of fetal SVT are highly diverse and that the most common patterns of initiation involve reentrant PACs. Both findings are unexpected. In a study of 22 infants, Dunnigan et al⁹ observed SVT initiation via atrial extrasystoles and sinus acceleration. Although they did not distinguish between extrasystoles attributable to spontaneous ectopy versus those attributable to reentry, it is generally assumed that SVT initiates with spontaneous ectopy, which is thought to be more common than reentry postnatally. In addition to spontaneous PACs and sinus acceleration, we observed one initiation pattern involving spontaneous antegrade block of the accessory connection in WPW and two patterns involving reentrant PACs, one of which used a second reentry pathway to sustain SVT. Five of eight subjects showed initiation with reentrant PACs, implying that this initiation pattern may predominate in the fetus. These subjects had heart rate and rhythm tracings that were complex but showed common features, such as frequent ectopy and intermittent atrial polygemy. In children, Dunnigan et al⁹ observed two additional initiation patterns, namely initiation with PVCs that block in the AV node and with junctional escape beats after sinus pause; however, PVCs and junctional escape beats were absent in our patients.

The characteristics of SVT in the fetus mirror those defined by classic electrophysiological and Holter monitor analysis in the neonate. These similarities include the following: (1) a high incidence of accessory AV connections as opposed to AV node reentry SVT; (2) presence of both concealed (or unidirectional) and manifest preexcitation; (3) presence of prolongation of VA conduction in association with aberrant QRS conduction during SVT; and (4) an association of SVT onset with prolonged AV conduction and subsequent reentry. In addition to these characteristics, the natural history of WPW in the fetus also seemed to mimic that seen in the neonate with the gradual intermittency or loss of preexcitation over time.

To our knowledge, no similar prior studies of the initiation and termination patterns of SVT have been performed in the fetus. The data presented here are valuable not only because they comprise the first fetal electrophysiological data but also because they represent natural initiation and termination. Much of the prior neonatal data comes from artificial SVT initiation using extrastimulus testing, ie, transesophageal pacing. However, as shown in this study, formation of a spontaneous PAC is only one of the ways in which SVT can initiate. The ability to discern natural patterns of initiation, as was demonstrated here, may be useful clinically, because certain drugs are more effective for suppression of spontaneous ectopy, for altering antegrade or retrograde conduction, or for treatment of particular types of tachycardia.

An important aspect of electrical rhythm monitoring is assessment of waveform morphology. This allows detection of such phenomena as WPW and QRS aberrancy, which cannot be seen with ultrasound. WPW was present in 2 of 8 subjects, and QRS aberrancy was common at the initiation of or within the first several beats of tachycardia in 4 of 8 subjects. Generally, aberrancy is associated with rapid rate or

shorter coupling intervals and is a distinguishing feature of SVT onset. Its absence in the fetus whose SVT initiated with sinus acceleration suggests adaptation to shorter coupling. QRS aberrancy has been shown to have importance for clinical SVT assessment. Goldstein et al¹⁰ demonstrated that QRS aberrancy is more common in the sicker infants with SVT. Aberrancy can also help lateralize the accessory connections, because in infants it is strongly associated with left-sided accessory connections. Finally, in fetuses being treated with medication, the presence of QRS aberrancy may reflect drug effect.

In the normal fetus, atrial ectopy is common, with an incidence of 1% to 3%. Approximately 1:200 fetuses with atrial ectopy are at risk for the development of SVT in utero or at up to 1 month of age.¹¹ Frequent ectopy was present in 4 of our subjects and could be distinguished as reentrant PACs versus spontaneous multifocal atrial activations on the basis of single atrial morphology and short, fixed coupling interval.

Evidence was seen for the existence of multiple retrograde and antegrade pathways and their involvement in the initiation and termination of SVT. The presence of multiple pathways is an additional risk factor for SVT. This suggests that fMCG can help identify which fetuses with ectopy are at higher risk for SVT on the basis of type of ectopy and number of reentrant pathways.

The underlying factors that trigger initiation and termination of SVT are largely unknown. The strong association between fetal trunk movement and the initiation and termination of SVT, revealed here by fMCG actocardiography, suggests that autonomic factors play a key role. Generally, fetal body movements are accompanied by increased sympathetic and decreased vagal tone.¹² Such changes in autonomic activity are compatible with the association seen here between fetal body movements and patterns of SVT initiation involving PACs and sinus acceleration.

More difficult to understand is the initiation of SVT attributable to block of the accessory connection in WPW. Although it is well known that exercise can cause sudden, rate-dependent block of the accessory connection in adult WPW patients, this explanation is unlikely in our patient, because sinus acceleration was absent at initiation. An alternative explanation is that block was attributable to concealed reentry involving one or more accessory connections. This is supported by the observation that this patient resembled patients 4 through 8 in the frequency of SVT episodes. We speculate that increased sympathetic activity attributable to fetal movement enhanced concealed retrograde conduction through alternate pathways. Another possible explanation is concealed reentry within the atrium.

fMCG provides an effective, noninvasive means of analyzing complex fetal rhythm patterns that potentially can overcome some of the shortcomings of ultrasound. It can aid in the differential diagnosis of ventricular tachycardia (VT) with

1:1 conduction versus SVT and of VT with AV dissociation versus junctional ectopic tachycardia. We recently studied one patient with VT and 1:1 conduction who was classified correctly on the basis of fMCG. In addition to rhythm assessment, the ability of fMCG to provide actocardiogram tracings was shown here to be very valuable. fMCG holds much promise as a clinical tool, but presently the technology is expensive and is available in only a few centers in the United States and abroad. Patients traveled as far as 150 miles to participate in the study. We believe that there is need to make this technique more widely available.

In conclusion, we have demonstrated the ability of fMCG to discern natural patterns of initiation and termination of fetal SVT. The data show that these patterns are much more diverse than previously believed and that the most common initiation pattern involves reentrant PACs. This capability can be exploited to better classify and treat fetal SVT. Other forms of serious fetal arrhythmias can be investigated in a similar manner. With additional development, the efficacy of fMCG for assessment of rhythm in utero may rival that of postnatal electrocardiographic monitoring.

Acknowledgments

This research was supported by grant R01HL63174 from the National Institutes of Health. We thank Mary Maier for making the fMCG recordings.

References

1. Naheed Z, Strasburger JF, Deal BJ, et al. Fetal tachyarrhythmia: mechanisms and predictors or hydrops fetalis. *J Am Coll Cardiol*. 1996;27:1736–1740.
2. Van Leeuwen P, Hailer B, Bade W, et al. Magnetocardiography in the diagnosis of fetal arrhythmia. *Br J Obstet Gynaecol*. 1999;106:1200–1208.
3. Hamada H, Horigome H, Asaka M, et al. Prenatal diagnosis of long QT syndrome using fetal magnetocardiography. *Prenatal Diagnosis*. 1999;19:677–680.
4. Wakai RT, Leuthold AC, Cripe L, et al. Assessment of fetal rhythm in congenital complete heart block by magnetocardiography. *PACE*. 2000;23:1047–1050.
5. Menendez T, Achenbach S, Beinder E, et al. Usefulness of magnetocardiography for the investigation of fetal arrhythmias. *Am J Cardiol*. 2001;88:334–336.
6. Ko JK, Deal BJ, Strasburger JF, et al. Supraventricular tachycardia mechanisms and their age distribution in pediatric patients. *Am J Cardiol*. 1992;69:1028–1032.
7. Chen M, Wakai RT, VanVeen B. Eigenvector-based spatial filtering of fetal biomagnetic signals. *J Perinat Med*. 2001;29:486–496.
8. Zhao H, Wakai RT. Simultaneity of fetal heart rate accelerations and fetal trunk movements determined by fetal magnetocardiogram actocardiography. *Phys Med Biol*. 2002;47:839–846.
9. Dunnigan A, Benditt DG, Benson DW Jr. Modes of onset (“initiating events”) for paroxysmal atrial tachycardia in infants and children. *Am J Cardiol*. 1986;57:1280–1287.
10. Goldstein M, Dunnigan A, Milstein S, et al. Bundle branch block during orthodromic reciprocating tachycardia onset in infants. *Am J Cardiol*. 1989;63:301–306.
11. Copel JA, Liang RI, Demasio K, et al. The clinical significance of the irregular fetal heart rhythm. *Am J Obstet Gynecol*. 2000;182:813–817.
12. Timor-Tritsch IE, Dierker LJ, Zador I, et al. Fetal movements associated with fetal heart rate accelerations and decelerations. *Am J Obstet Gynecol*. 1978;131:276–280.